

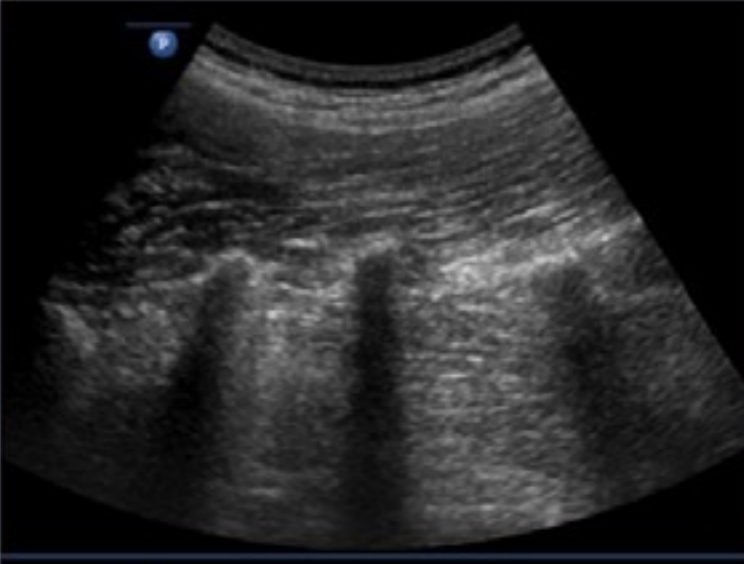







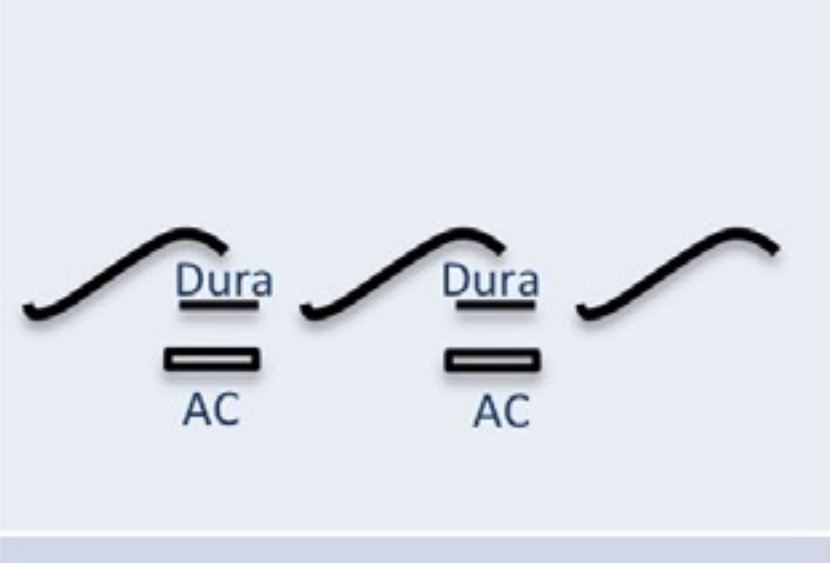


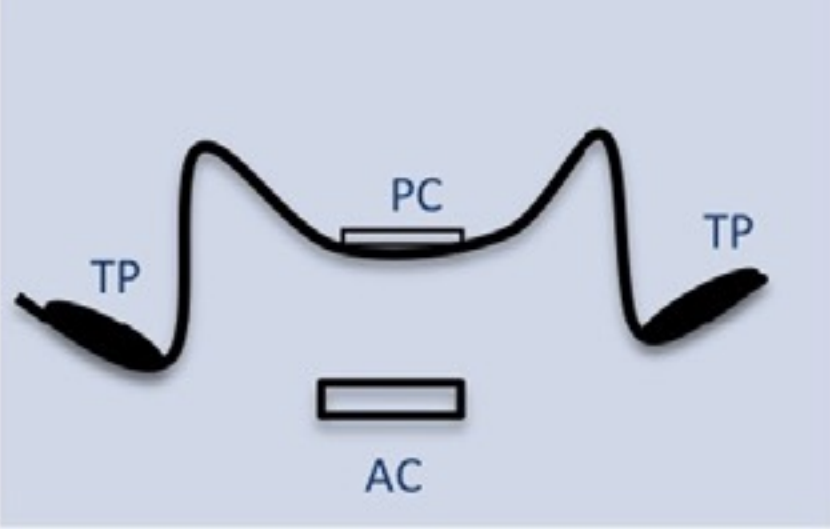
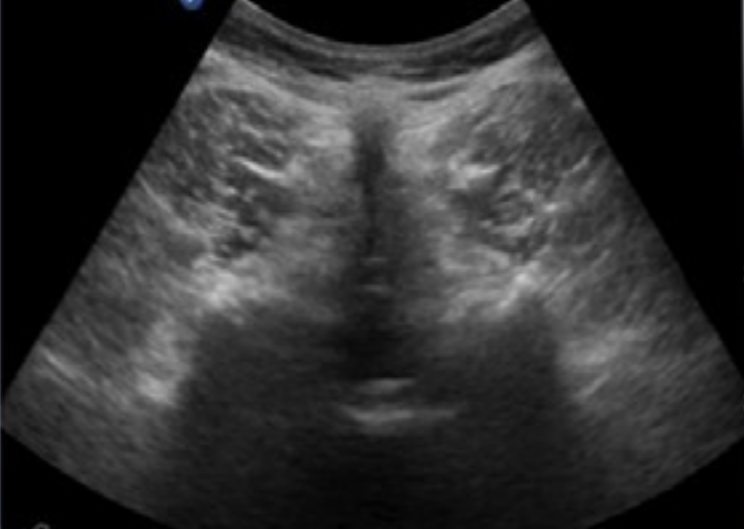


View	Probe orientation	Pattern recognition image	Ultrasound view	Notes
Paramedian Sagittal Transverse Process View				The “trident sign” represents finger-like shadowing behind the transverse processes.
Paramedian Sagittal Articular Process View				“Camel humps” represent continuous hyperechoic bone, due to vertebrae being connected by articular processes.
Paramedian Sagittal Laminar View				“Sawtooth” or “Horse Heads” represent the laminae, the hyperechoic bone is not continuous and the interlaminar space allows visualization of the posterior and anterior complex.
Paramedian Sagittal Oblique View				Slight medial tilt optimizes the view of the posterior and anterior complexes. The dura is seen as a thin hyperechoic line.
Transverse Interlaminar view				The articular processes/facet joints and transverse processes (TP) are visible. Tilting the probe will highlight the posterior (PC) and anterior (AC) complexes.